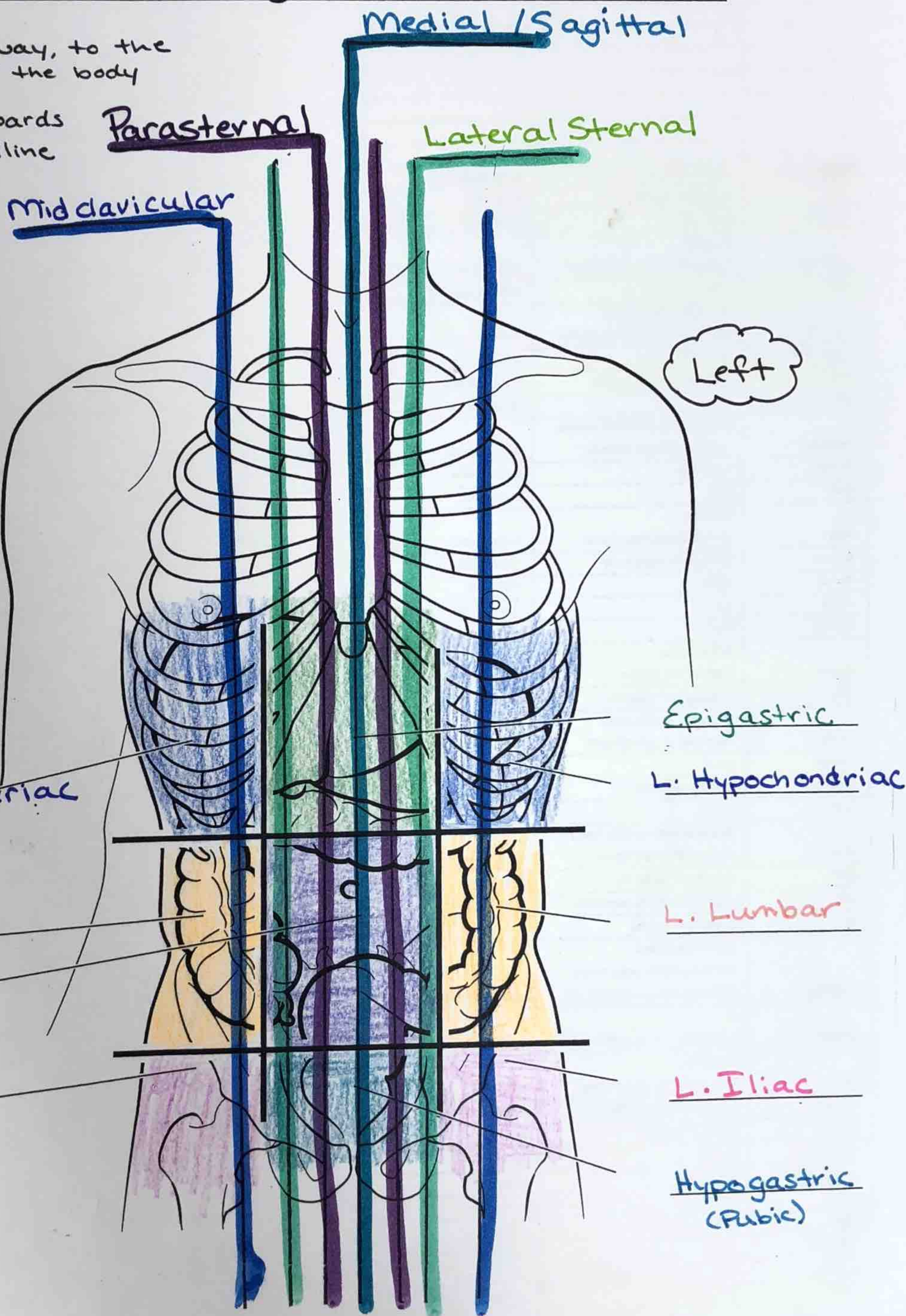


Abdominal Regions and Incisions

Lateral = away, to the edge of the body

medial = towards the midline

Transverse = horizontally across



Right

Left

R. Hypochondriac

Epigastric
L. Hypochondriac

R. Lumbar

L. Lumbar

Umbilicus

R. Iliac

L. Iliac

Hypogastric (Pubic)